


PATIENT PRESENTING CLINICAL SIGNS

Gus McAulsan
 History: Recheck echo.
 -Current medications Pimobendan, will be on Traz for echo, aventi liver, metacam
 -Abnormal PE/Chem/CBC/UA Results: Elevated ALP, mildly elevated albumin, free T4 WNL.
SPECIES
 Canine
 -Radiographs: Showed moderate cardiomegaly (VHS 11.7) with PV dilation.
 -Pertinent previous echo findings (7/2022 MML): Moderate MR, moderate LAE, mild LVE, no TR. LA: 2.4, LV: 3.5

BREED ECHOCARDIOGRAM FINDINGS

Norfolk Terrier
 2D, m-mode, color flow and doppler imaging is available. Diffuse thickening of mitral valve leaflets (anterior>posterior) with no prolapse into the left atrial lumen. Moderate eccentric mitral regurgitation with moderate left atrial dilation. Normal MR velocity. Mildly increased LV diameter with hyperdynamic myocardial function. The tricuspid valve appears mildly thickened with no significant tricuspid regurgitation. Normal right atrial and ventricular diameter. The pulmonic and aortic valves are normal in morphology and mobility. Normal pulmonic and aortic outflow velocities. No aortic or pulmonic insufficiency. No pericardial or pleural effusion noted. No cardiac tumors observed.

SEX

Male Neutered

AGE

10 years

CARDIAC CHART
WEIGHT
 15.4lbs

CANINE CARDIAC PARAMETERS	MR VMAX (m/s)	TR VMAX (m/s)	LA/AO (Boon method)	LA/AO (Heart Base; Swe)	FS (%)	EF (%)	EPSS (cm)
NORMAL PARAMETER	4.5-5.5	<2.7	1.3	<1.6	28-40	40-100	<0.6
PATIENT	5.7	NA	1.4	1.8	51	85	NM
CANINE CARDIAC PARAMETERS	HR (BPM)	AV VMAX (m/s)	PV MAX (m/s)	BODY WEIGHT (kg)	LA 2D short axis Base view (cm)	LVIDd Avg; 2D and m-mode short axis (cm)	LVIDs Avg; 2D and m-mode short axis (cm)
NORMAL PARAMETER	50-100	0.7-1.7	0.7-1.6	BELOW	BELOW	BELOW	BELOW
PATIENT	170	2.3	1.8	7.0	2.6	3.2	1.4
*Normal chamber parameters expressed as a mean value (SD)				3	1.27 (5.3)	2.46 (2.46)	1.36 (5.5)
BODY WEIGHT DEPENDENT PARAMETERS				5	1.40 (4.5)	2.74 (5.2)	1.60 (4.7)
*Note: All measurements based upon multi-modal images and methods. An average value is reported.				10	1.50 (3.8)	3.27 (3.5)	2.06 (3.1)
				15	1.83 (2.0)	3.71 (2.4)	2.43 (2.1)
				20	2.02 (1.9)	4.14 (2.2)	2.80 (2.0)
				25	2.18 (2.4)	4.48 (2.9)	3.10 (2.5)
				30	2.33 (3.3)	4.83 (3.9)	3.39 (3.4)
				35	2.48 (4.3)	5.17 (5.0)	3.69 (4.5)
				40	2.62 (5.2)	5.48 (6.1)	3.96 (5.4)
				50	2.88 (7.1)	6.07 (8.3)	4.46 (7.4)

INTERPRETED BY

 Maggie Machen Lamy,
 DVM DACVIM
 (Cardiology)

IMAGING PERFORMED BY

Kelly Reschny, RVT

HOSPITAL NAME

 Headon Forest
 Animal Hospital

REFERRING VET

Dr. Monsjou

INTERPRETATION OF THE FINDINGS & FURTHER RECOMMENDATIONS

INVOICE
 29096
DATE
 2/17/23

Persistently stable disease is identified in this study. Moderate mitral regurgitation is unchanged with stable left heart dimensions. No additional issues have developed.



PATIENT

Gus McAulsan

Given these findings, continue Pimobendan lifelong. Assessment of progression in the future will help predict long term outcome, however prognosis is guarded at this stage (B2).

SPECIES

Canine

Omega fatty acid supplementation and mild salt restriction may also be of some long-term benefit. Monitor for development of a progressive cough, labored breathing, exercise intolerance or collapse episodes.

BREED

Norfolk Terrier

Anesthetic risk is considered mildly elevated. Cardiac protective drug choices (opioid/benzodiazepine premedication, Propofol or alfaxalone induction, iso or sevo gas) are recommended. Monitor for arrhythmias, hypotension, and hypoxia both intra and post-operatively and intervene as necessary. Judicious IV fluid rates are recommended to avoid fluid overload. Avoid heart rate stimulating drugs such as atropine unless clinically indicated.

SEX

Male Neutered

AGE

10 years

PLAN

Continue Pimobendan as prescribed. Monitor BP is recommended.

Recommend monitor for progression with a recheck echocardiogram in 6 months, sooner if any development of clinical signs.

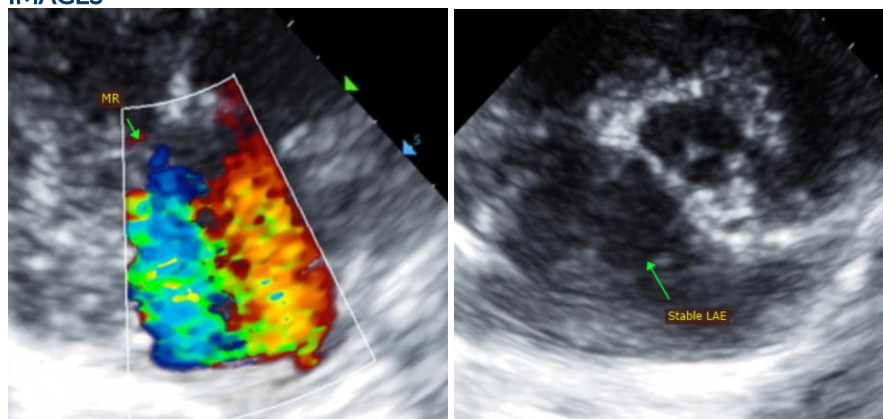
WEIGHT

15.4lbs

IMAGES

INTERPRETED BY

Maggie Machen Lamy,
DVM DACVIM
(Cardiology)



IMAGING PERFORMED BY

Kelly Reschny, RVT

HOSPITAL NAME

Headon Forest
Animal Hospital

The information and recommendations provided are based on the images presented by the referring veterinarian. No evaluation can be communicated regarding pathology that was not visible in the image/video clips provided.

REFERRING VET

Dr. Monsjou

Thank you for this referral. This report was generated using transcription software, and minor dictation errors may be present. If the clinical or image interpretation does not parallel your findings or if I can be of any further assistance, please contact me.

INVOICE

29096

Maggie Machen Lamy, DVM
Diplomate of the American College of Veterinary Internal Medicine (Cardiology)
info@sonopath.com

DATE

2/17/23